

GB 21

Location

In the upper fibres of trapezius at the highest point of the shoulder; midway between C7 and the acromion

Anatomy

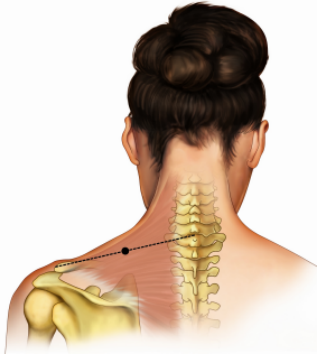
Muscle: The upper portion of the trapezius

Nerve: Accessory nerve

Blood vessel: Branch of the transverse cervical artery

Technique

Insert needle 0.5 – 1.0 cun perpendicular to the surface; need to avoid injury to the lung



May not be exactly as shown in the 2009 course syllabi